

Case Report



A special case of acute portal vein thrombosis

Xin Li¹, Zhoupeng Wu²

1.Department of ultrasound, West China Hospital, 37 GuoXue Alley, Chengdu 610041, Sichuan Province, China.

2.Department of vascular surgery, West China Hospital, 37 GuoXue Alley, Chengdu 610041, Sichuan Province, China.

*Corresponding Authors: Zhoupeng Wu; E-mail: lzwzp19@163.com

Abstract

Among the risk factors and underlying etiology of acute portal vein thrombosis, viral hepatitis is an extremely rare cause. We report a case of a young healthy 40-year-old male who was diagnosed with acute hepatitis A virus infection and presented with acute portal vein thrombosis. This article describes the possible pathophysiological mechanisms, clinical symptoms, and treatment of acute portal vein thrombosis in this patient. Based on this patient's history and treatment, we encourage testing for hepatitis A serological markers in the emergency department in a population with recent hepatitis A exposure risk factors and concurrent unexplained acute portal thrombosis.

Key words Portal vein thrombosis; Hepatitis; Etiology; Treatment

Introduction

Portal vein thrombosis (PVT) can occur in any segment of the portal vein. The etiology of more than half of the cases is unknown, but may be related to systemic or local infection (eg, suppurative portal phlebitis, cholecystitis, lymphadenitis of adjacent sites, pancreatitis, and liver abscess). PVT occurs in 10% of patients with cirrhosis and is often complicated by hepatocellular carcinoma. PVT can also occur in pregnancy (especially in patients with eclampsia) and in patients with portal vein congestion (eg, hepatic vein occlusion, chronic heart failure, constrictive pericarditis). PVT can also be caused when tumors of the pancreas, stomach, or other sites invade the portal vein. Similar to Budd-Chiari syndrome, thrombophilic hematologic conditions can also lead to PVT. It can also be seen after hepatobiliary surgery or splenectomy. Cytomegalovirus (CMV), hepatitis B, and hepatitis C infections can lead to a hypercoagulable state that increases the risk of PVT²⁻³. In contrast, hepatitis A virus (HAV) with any form of venous thromboembolism (VTE) have been reported extremely rarely, with only one report in the literature describing cerebral venous thrombosis associated with HAV infection and one case with portal vein thrombosis^{4,5}. We reported a patient with acute PVT who was diagnosed with acute hepatitis A virus infection in the emergency department.

Case Presentation

A 40-year-old male presented to the emergency department with right upper abdominal pain and jaundice. The patient was previously healthy. The patient underwent splenectomy in the local hospital 8 years ago due to traffic accident injury. At the same time, there was no obvious abnormality during the follow-up with ultrasound during the 8 years. After eating in the local seafood restaurant two weeks ago, he began to suffer from general fatigue, decreased appetite and gradually deteriorated. Then during this week, there was pain in the right upper abdomen, yellow eyes and skin, accompanied by night sweat and low fever. The patient had no family history of thrombotic disease, and he also denied drug addiction. Positive signs on his physical examination included abdominal distension, tenderness of the right upper abdomen, yellowing of the skin and sclera, and edema

of the lower limbs. Blood examination showed that blood ammonia (56.8 μmol/L), alkaline phosphatase (365 IU/L), AST and ALT (154 IU/L and 165 IU/L) were significantly increased, while total bilirubin was 7.6 mg/dl (0.1-1.2 mg/dl) and direct bilirubin was 6.8 mg/dl (0.0-0.3 mg/dl). In addition, the patient's white blood cell count was also significantly increased, the platelet was $76 \times 10^9/L$, D-dimer was elevated and prothrombin time (PT) was prolonged in patients (INR 2.1). The serum anti hepatitis A immunoglobulin M (IgM) antibody was high titer positive (repeated three times). The CT examination of the patient showed that the liver was mildly enlarged, and thrombus appeared in the main portal vein and superior mesenteric vein, with a small amount of ascites (Fig. 1AB).

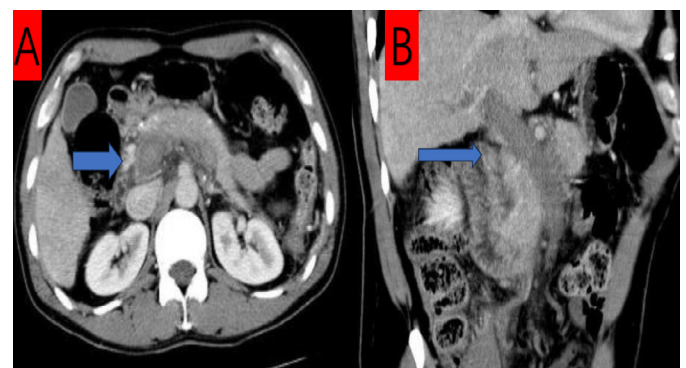


Fig 1A: portal vein-superior mesenteric vein extensive thrombosis; 1B: superior mesenteric vein thrombosis

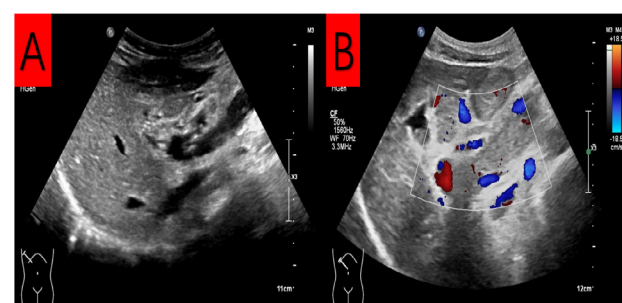


Fig 2 Follow-up abdominal vascular color Doppler ultrasound. A: The superior mesenteric vein thrombus disappeared; 2B: The old thrombus in the portal vein

Abdominal ultrasound examination revealed portal vein thrombosis, which was consistent with the CT report.

The patient started anticoagulant therapy with low molecular weight heparin and was screened for the etiology of thrombosis. The results of blood serological examination were negative: HBsAg, anti HBC, anti HBS, anti HBE, HBeAg, anti - HBCGM, anti HCV, anti HDV and HIV. Meanwhile, the levels of antithrombin III, factor V Leiden and protein C and protein S were also within the normal range. The blood immunologic indexes including anti nuclear antibody (ABS), anti mitochondrial antibody, anti cardiolipin IgM and IgG, rheumatoid factor, anti connective tissue protein, anti DS DNA antibody, anti SM antibody, c-anti neutrophil cytoplasmic antibody (C-ANCA), P-ANCA and anti thyroid peroxidase antibody were also negative. No cryoglobulin was detected in the serum.

The patient continued to receive conservative treatment. The symptoms of the patient began to improve and the liver enzymes returned to normal. At the same time, the patient insisted on the anticoagulant treatment of rivaroxaban for 6 months. During the follow-up of 3 months and 6 months, the patient performed well. At the same time, the blood test showed that IgG antibody against hepatitis A virus appeared, and the serum IgM antibody level also decreased significantly. Follow up abdominal ultrasound showed old thrombus in the main portal vein with partial recanalization (Fig.2AB).

Discussion

VTE is a disease caused by many factors⁶. Generally speaking, these risk factors include acquired, environmental and genetic possibility. When these risk factors are combined together, VTE may occur. Although viral hepatitis often does not lead to acute portal vein thrombosis, acute infection may be associated with an increased risk of transient VTE⁶⁻⁷.

Various factors can lead to abnormal hemostasis, viral hepatitis can play an important role, and virus can down regulate the physiological anticoagulant mechanism, inhibit fibrinolysis and tissue factor mediated thrombin growth⁸. At present, the existing literature reports that viral infection may be related to anti phospholipid antibodies. Meanwhile, a recent study shows that the risk of thrombosis may be greater than the risk of bleeding in patients with chronic liver disease⁹. Finally, acute viral hepatitis can activate coagulation cascade by contacting portal vein endothelial cells, thus causing inflammatory changes.

Hepatitis A virus infection is more common in low socio-economic areas, where the lack of adequate sanitation facilities and poor sanitation conditions spread the infection¹⁰. The mode of transmission of this virus is the fecal oral route. The sudden onset of hepatitis A virus infection usually begins with premonitory symptoms, including nausea, vomiting, anorexia, fatigue, fever and uremia. Hepatitis A virus infection is usually an acute, self limiting disease, rarely leading to fulminant liver failure. Hepatitis A virus infection often does not have extrahepatic manifestations. At present, there are only skin vasculitis, cold globulinemia, cholecystitis, and Guillain Barre disease¹¹. To a certain extent, the diameter of the portal vein is positively correlated with portal vein pressure in patients with hepatitis virus infection. The larger the diameter of the portal vein, the higher the portal hypertension and the slower the flow velocity of the portal vein, sequentially. However, a larger portal vein diameter is often associated with injured venous

intima. Therefore, enlarging the portal vein diameter can stimulate the formation of thrombosis, regardless of the surgical procedure performed¹²⁻¹⁴.

In this case, the time correlation between hepatitis A virus infection and acute portal vein thrombosis and the absence of other prethrombotic lesions in this patient led us to conclude that hepatitis A was the causative factor of this acute portal vein thrombosis. To our knowledge, acute portal vein thrombosis caused by hepatitis A virus is an extremely rare case, and it is also a rare case of VTE caused by hepatitis A virus infection.

Reference

1. Italian Association for the Study of the Liver (AISF), AISF Expert Panel, AISF Coordinating Committee, et al. Position paper of the Italian association for the study of the liver (AISF): the multidisciplinary clinical approach to hepatocellular carcinoma. *Dig Liver Dis* 2013;45:712–23. doi: 10.1016/j.dld.2013.01.012
2. Nery F, Chevret S, Condat B, et al. Causes and consequences of portal vein thrombosis in 1,243 patients with cirrhosis: results of a longitudinal study. *Hepatology* 2015;61:660–7. doi: 10.1002/hep.27546
3. Trebicka J, Strassburg CP. Etiology and complications of portal vein thrombosis. *Viszeralmedizin* 2014;30:375–80. doi: 10.1159/000369987
4. Zis P, Kontogeorgi E, Karakalos D, et al. Cerebral venous thrombosis as an extrahepatic manifestation of acute anicteric hepatitis A infection. *Case Rep Neurol Med* 2012;2012:120423. doi: 10.1155/2012/120423
5. Abulawi A, AL-Tarbsheh A, Tageldin O, et al. Acute portal venous thrombosis as an extrahepatic manifestation of acute hepatitis A infection. *BMJ Case Rep* 2022;15:e250177 doi: 10.1136/bcr-2022-250177
6. Denninger MH, Chaït Y, Casadevall N, et al. Cause of portal or hepatic venous thrombosis in adults: the role of multiple concurrent factors. *Hepatology* 2000;31:587–91. doi: 10.1002/hep.510310307
7. Smeeth L, Cook C, Thomas S, et al. Risk of deep vein thrombosis and pulmonary embolism after acute infection in a community setting. *Lancet* 2006;367:1075–9. doi: 10.1016/S0140-6736(06)68474-2
8. Levi M, Keller TT, van Gorp E, et al. Infection and inflammation and the coagulation system. *Cardiovasc Res* 2003;60:26–39. doi: 10.1016/s0008-6363(02)00857-x
9. Zignego AL, Ferri C, Pileri SA, et al. Extrahepatic manifestations of hepatitis C virus infection: a general overview and guidelines for a clinical approach. *Dig Liver Dis* 2007;39:2–17. doi: 10.1016/j.dld.2006.06.000
10. Tripodi A, Mannucci PM. The coagulopathy of chronic liver disease. *N Engl J Med* 2011;365:147–56. doi: 10.1056/NEJMra1011170
11. Sook-Hyang Jeong, Hyo-Suk Lee. Hepatitis A: clinical manifestations and management. *Intervirology*.2010;53:15-9 doi: 10.1159/000252779
12. Jie Chen, Xianmao Shi, Tao Luo et al. The correlations between hepatitis B virus infection and hepatocellular carcinoma with portal vein tumor thrombus or extrahepatic metastasis. *Eur J Gastroenterol Hepatol*.2020;32:373-7. doi: 10.1097/MEG.0000000000001514
13. Long Fei Wu ,Dou Sheng Bai, Lin Shi et al. Predictors of portal vein thrombosis after laparoscopic splenectomy and azygoportal disconnection in hepatitis B cirrhosis: a prospective study. *Surgical Endoscopy* 2022 ;36:4090–8 doi: 10.1007/s00464-021-08730-5
14. Elleuch N, Moalla M, Mahmoud S et al. Spectrum of acute hepatitis and its clinical outcome in a central region in Tunisia. *Pan Afr Med J*. 2021 ; 40:53 doi: 10.11604/pamj.2021.40.53.25725