

# Topographic and Morphometric Assessment of Facial Foramina in Maxilla, Mandible, and Zygomatic Bones: Anatomical and Clinical Relevance

Sevindik Betul<sup>1,\*</sup>, Ozcan, Ayse Gamze<sup>1</sup>, Pirinc, Busra<sup>1</sup>, Unver Dogan<sup>1</sup>, Nadire<sup>1</sup>

1. Department of Anatomy, Faculty of Medicine, Selcuk University, Konya, Türkiye

\* Corresponding Author: Sevindik Betul ; E-mail: drbetulsevindik@gmail.com

## Abstract

### Background

The anatomy of the zygomatic bone, maxilla, periorbital, and mental regions is important because important vessels and nerves pass through these regions. The zygomaticofacial nerve can be injured during facial surgeries, especially during zygomatic implant surgeries. Infraorbital and mental nerves are among the nerves blocked during local anesthesia in dentistry.

### Objective

To evaluate the topographic and morphometric characteristics of the zygomaticofacial, infraorbital, and mental foramina, and to determine their anatomical variations and clinical significance in order to provide guidance for maxillofacial surgical procedures and regional anesthesia applications

### Methods

30 dry human skull bones (60 sides) were examined. The distance of the zygomaticofacial foramen to the edge of the orbit, the distance to the lower end of the zygomaticomaxillary suture, the distance to the upper end of the zygomaticotemporal suture, and the distance to the infraorbital foramen were measured. The distance of the infraorbital foramen to the edge of the orbit and the lower end of the suture zygomaticomaxillaris was measured. Morphometric measurements of the mental foramen variations were examined.

### Results

Distance between infraorbital foramen and zygomaticomaxillary suture found 24.42 mm on the right; 25.21 mm on the left. It was statistically significant ( $p = 0.030$ ). The location of the zygomaticofacial foramen was evaluated in four regions (A, B, C, and D), and the most frequent location was region A.

### Conclusion

Determining the area where the zygomaticofacial foramen is most commonly located will serve as a guide to help prevent nerve injury during facial surgery. It is important that there is no significant difference in the distances between the foramina on the right and left sides to facilitate surgical interventions.

**Key Words:** Anatomy, Variation, Infraorbital foramen, Mental foramen, Zygomaticofacial foramen

## Introduction

The anatomy of the zygomatic bone, maxilla, periorbital and mental region are important due to the important vessels and nerves passing through that regions. Especially the zygomatic bone is an important anatomical structure in facial surgeries<sup>1</sup>. Nerve blockade in this area is often required for facial wound closure, biopsies, wound revisions, and other cosmetic skin procedures<sup>2</sup>. The zygomaticofacial nerve can be injured during facial surgeries, especially during zygomatic implant surgeries. Infraorbital and mental nerves are among the nerves blocked during local anesthesia in dentistry. Knowing the location of the mental foramen and mental nerve in complex intraoral surgical interventions is important to prevent possible complications.

The zygomatic nerve and its zygomaticofacial branches pass through the zygomaticofacial foramen (ZFF), passing laterally from the orbit. This point is used as a reference in orbitozygomatic craniotomies, therefore variations in this foramen are important<sup>3</sup>. There is a possibility of damage to the zygomaticofacial nerve in craniofacial operations

and various dermocosmetic applications. Knowing the location and variations of the ZFF is useful in preventing these complications<sup>4</sup>. Zygomatic implants are the preferred method in dentistry for patients who do not have sufficient maxillary bone to anchor a dental implant, thus avoiding the need for extensive bone grafting<sup>5</sup>. ZFF and zygomatic nerve localization is also important in malar reduction surgeries. The possibility of nerve injury is high in osteotomies in this region<sup>6</sup>. It has also been emphasized in the literature that ZFF is an anatomical marker that enables anthropological distinction<sup>5</sup>.

The infraorbital and mental nerves are blocked through the infraorbital and mental foramen to provide local anesthesia during dental, plastic, and oromaxillofacial surgeries<sup>7</sup>. The infraorbital nerve is a continuation of the maxillary nerve and exits through the infraorbital foramen (IF). It contains sensory branches that supply the skin of the upper cheek, the mucosa of the maxillary sinus, the maxillary incisor, canine and premolar teeth and adjacent upper gums, the skin and conjunctiva of the lower eyelid, part of the nose, and the skin and mucosa of the upper lip. In order to block

this nerve, the foramen must be found by palpating the infraorbital rim. Therefore, its distance to the orbital rim is also important<sup>8</sup>. Determining the location of the foramen is of great importance for both diagnostic and clinical procedures related to the mandible. Knowing the distances of the mental foramina to the midline allows the definition of safe areas during mandibular surgery. Clinically, the mental nerve bundle emerging from the mental foramen may be injured during surgical procedures, which may cause paresthesia or anesthesia in the area of sensory distribution of the nerve. Sometimes, panoramic radiographs may also be used to locate the mental foramen<sup>9</sup>.

Craniofacial asymmetries can be seen in humans without any pathological condition. Right and left asymmetry can affect chewing functions and can also cause cosmetic problems. These asymmetries are generally observed in the majority of the population. Genetic and environmental factors affect this situation. It has been argued that gender and age have no effect on asymmetry<sup>10,11</sup>. In particular, due to the key role of the zygomatic bone in the structure and aesthetic appearance of the face, the evaluation of bilateral asymmetry is of great importance<sup>12</sup>.

## Methods

Measurements were performed on 30 intact dry skull bones (60 sides) from XXX University's bone collection. A total of 13 skulls that were fractured or had compromised integrity were excluded from the study. We did not have information about the age and gender of the bones. Ethical approval was obtained from the XXX University Non-Interventional Research Ethics Committee (Approval Number:2024/295; Date:04.06.2024). Digital caliper (Insize 1108/Suzhou, People's Republic of China) with a measuring range of 0-150 mm and an accuracy of 0.03 mm was used to measure the parameters. Caliper correction was performed before each measurement. Measurements were made twice by the same observer and the average was taken. The zygomatic region was divided into four regions based on the work of Aksu et al [1]. A line drawn lateral to the orbital rim and a horizontal line drawn from the lowest point of the orbital rim were determined to intersect each other at a 90-degree angle. The number and regional location of the zygomaticofacial foramina were examined (Figure 1).

The perpendicular distance of the ZFF to the orbital edge, the distance to the infraorbital foramen, the distance to the lower edge of the zygomaticomaxillary suture (ZMS), and the distance to the upper edge of the zygomaticotemporal suture (ZTS) were measured. In bones with more than one foramen, distance was measured according to the largest ZFF for measurements.

The perpendicular distance of the infraorbital foramen to the edge of the orbit and the distance to the lower end of the zygomaticomaxillary suture was measured. The numbers of infraorbital foramina on the right and left sides were evaluated. ZFF and infraorbital foramen measurements are given in Figure 2.

The distance between the angle of the mandible and the mental foramen, as well as the distance between the angle of the mandible and the midline, were measured. In addition, the position of the mental foramen relative to the mandibular teeth was examined, and its variations were evaluated (Figure 3).

Statistical analyses in the study were performed using SPSS

27.0 (IBM Inc., Chicago, IL, USA) program. Descriptive statistics of the numerical and categorical data were analyzed, and the numerical parameters were summarised as interquartile range (IQR) and was expressed as median (min-max), while the categorical variables were expressed as frequency and percentages (%). Proportional values were compared with z scores and p values. Comparison of right and left-side findings was assessed with Wilcoxon analysis. Significant comparisons are summarized with box-plot graphics. In the entire study, the type-I error rate was taken as 5%, and  $p < 0.05$  was considered significant.

## Results

Morphometric measurements of ZFF and IF are given in the table for both sides (Table 1). Distance between infraorbital foramen and zygomaticomaxillary suture found 24.42 mm on the right; 25.21 mm on the left. It was statistically significant ( $p = 0.030$ ) (Figure 4).

We found ZFF most frequently in "region a" and least frequently in "region d" on both the right and left sides. The distribution by region is given in Table 2. Max 3, min 0 ZFF were encountered on the right and left sides.

The mental foramen was located most frequently between the first and second premolar teeth on the right side (right 36%). On the left side, it was equally localized between the 1st and 2nd premolar (33%) and midline of the 2nd premolar (33%) (Table 3). There was no significant difference between the distance measurements of the right and left sides when comparing the mental foramen. Morphometric measurements of the mental foramen are given in Table 4.

## Discussion

The major facial foramina and the nerves that pass through them are crucial for particularly in maxillofacial surgery, regional anesthesia, and minimally invasive aesthetic procedures such as filler injections. The locations of these points should be well known to minimize nerve and vascular injuries and prevent complications. Determining the area where the zygomaticofacial foramen is most commonly seen will be a guide in preventing nerve injuries in facial surgeries. Due to the anatomical significance of ZFF, when we examine its distances to certain points, we can find studies in the literature measuring the distance between ZFF and ZMS. Aksu et al. found the distance between ZFF and ZMS to be 18 mm on average<sup>1</sup>. We measured it as 19.7 mm. Our results were similar to the values of Aksu's study. Malevez et al. emphasized that the zygomatic implant is an alternative method that can be preferred for dental prostheses in patients who do not have sufficient upper jaw bone mass<sup>13</sup>. The ZFF serves as a critical anatomical landmark in subperiosteal midface lift and orbitozygomatic craniotomy procedures. Grant reported that the foramen lies approximately 6 mm inferior to the inferior orbital edge<sup>14,15</sup>. In our study, we found this distance to be 7.40 mm on the right and 6.90 mm on the left. The values we found can be considered similar to the literature. Kim Hong et al. emphasized that especially the location of the zygomaticofacial foramen should be known in terms of nerve paresthesias in this region in surgical interventions that may be performed on the middle 1/3 of the face. The localization of the ZFF demonstrates considerable variation. In this study, the reference points described by Aksu et al. were adopted to classify ZFF localization. Aksu et al. reported that the most frequent location of the ZFF was region C (46%). Similarly, Deana et al. identified region

**Table 1. Comparison of left and right measurements**

	RIGHT			LEFT			p
	Median (min-max)	Mean	SD	Median (min-max)	Mean	SD	
Perpendicular distance of ZFF to infraorbital edge	7.03 (0-15)	7.40	2.87	6.6 (0-11.75)	6.90	2.06	0.992
Distance of ZFF to infraorbital foramen	25.4 (13.91-34.4)	25.70	4.77	26 (20.06-37.15)	26.75	4.26	0.096
Distance of ZFF from the lower edge of ZMS	19.05 (12.88-27.23)	19.46	3.26	19.9 (12.44-27.2)	19.97	3.51	0.204
Distance of ZFF from the upper edge of the ZTS	20.18 (11.98-29)	19.87	3.56	18.73 (10.53-26.4)	18.64	3.50	0.191
Perpendicular distance of IF to infraorbital edge	7.9 (4.17-10.6)	7.88	1.74	7.95 (4.5-11.2)	7.84	1.90	0.888
Distance between IF and ZMS	24.73 (19.5-31.39)	24.42	2.88	25.65 (20.14-31.2)	25.21	2.95	0.030*

SD=standard deviation; ZMS = Zygomaticomaxillary suture; ZFF= Zygomaticofacial foramen; ZTS=Zygomaticotemporal suture; IF= Infraorbital foramen.

Comparisons are based on median values (IQR); Wilcoxon test.

**Table 2. Descriptive summary of the region locations of the ZFF.**

Zygomaticofacial foramen	
Right sided foramen	
Region – A	23 (39.66%)
Region – B	13 (22.41%)
Region – C	14 (24.14%)
Region – D	8 (13.79%)
Left sided foramen	
Region – A	22 (44.0%)
Region – B	9 (18.0%)
Region – C	8 (16.0%)
Region – D	11 (22.0%)

Comparison of the two proportions (left and right):  $z=1.089$ ;  $p=0.276$ .

**Table 3. Descriptive summary of right and left locations of mental foramen.**

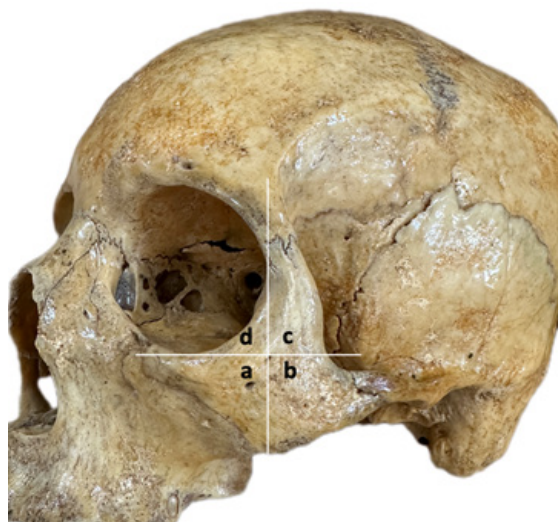	RIGHT		LEFT	
	N	%	N	%
Medial of 1st premolar	1	3.3%	1	3.3%
Between the 1st and 2nd premolars	11	36.7%	10	33.3%
Midline of the 2nd premolar	9	30.0%	10	33.3%
Lateral of 2nd premolar	9	30.0%	9	30.0%
Total:	30	100%	30	100%

C as the most common location (59%). In contrast, in our study, the ZFF was most frequently observed in region A (41%), whereas it was observed in region C at 20%. Knowing the location where ZFF is frequently found is important, especially in terms of preventing injury to the neurovascular complexes passing through this foramen. Taking variations into account before surgical planning will also reduce the risk of complications during the operation. It will also contribute to determining reference points to prevent nerve injury. The number of zygomaticofacial foramina varies

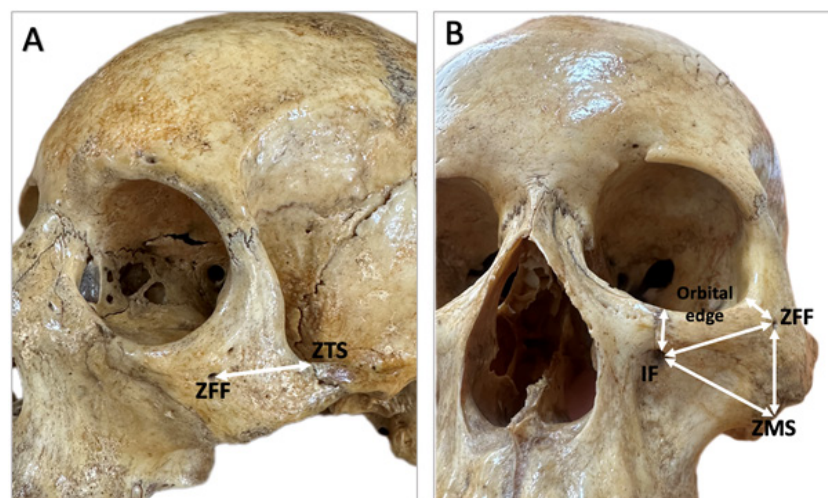
greatly. Sometimes there may be none, sometimes there may even be five. The variation in the number of ZFF is due to the numerical variation of the ossification centers of the zygomatic bone during the embryological period<sup>16</sup>. The incidence of multiple ZFF is particularly high in the Kenyan population, with approximately 54% of individuals having more than one ZFF. This anatomical variation may cause the zygomaticofacial nerve to reach superficial tissues via multiple branches. Therefore, the presence of multiple ZFF may increase the failure of local anesthesia applied to

**Table 4. Comparison of left and right measurements of mandible.**

	RIGHT			LEFT			p
	Median (min-max)	Mean	SD	Median (min-max)	Mean	SD	
Vertical diameter of mental foramen	2.09 (1.30-3.70)	2.19	0.55	2.03 (1.18-4.82)	2.16	0.70	0.674
Horizontal diameter of mental foramen	2.59 (1.67-5.90)	2.84	0.86	2.85 (1.65-5.70)	2.93	0.94	0.226
Measurement between angle of mandible and mental foramen	59.35 (47.15-77.92)	60.50	7.18	60.20 (48.20-74.28)	60.95	6.50	0.462



**Figure 1: Regional location of ZFF**



**Figure 2: Representation of the distances of the foramina to the specified points on the bone (ZFF: Zygomaticofacial foramen, ZTS: Zygomaticotemporal suture, IF: Infraorbital foramen, ZMS: Zygomaticofacial suture)**

the face and increase the risk of iatrogenic nerve damage in surgical interventions (e.g., orbitozygomatic fracture repairs, aesthetic or reconstructive facial surgery). The evaluation of the number of ZFF with preoperative imaging is critical for surgical planning and anesthesia success<sup>17</sup>. In our study, we found the number of ZFF to be a maximum of 3 on the right and left sides, and there was no unilateral ZFF in 2 bones (3.3%). One of the most important reference points used to determine the location of the infraorbital foramen is the infraorbital edge. Variations in the location of IF may cause the local anesthetic agent not to be injected to the required place and lead to insufficient anesthesia. There are many studies that measure the distance of the infraorbital foramen to this distance. The average values found in these studies are between 5-10 mm. A distance below 5 mm is risky, especially in needle medical applications, in terms of the needle advancing into the eye. In cases where the distance is short, the practitioner should be more careful during

interventional procedures<sup>18-21</sup>. We measured the distance of the infraorbital foramen to the orbital edge as 7.88 mm on the right and 7.84 mm on the left. Aggarwal et al. reported that the foramen was 5–8.5 mm from the infraorbital edge in 75% of the bones<sup>22</sup>. This is similar to our mean values for the right and left. In a study of dry skulls from an Indian population, the mean distance to the infraorbital edge was reported as 8.48 mm, which is higher than the values observed in our study<sup>23</sup>. Although our measurements of the perpendicular distances of ZFF and IF to the infraorbital edge did not show significant bilateral differences, their variability (as reflected in standard deviations) suggests that individual anatomical variation is considerable. For instance, the perpendicular distance of the ZFF to the infraorbital edge ranged from 0 to 15 mm, which highlights the need for individualized preoperative imaging or palpation. These findings advocate for the practice of customizing procedure planning rather than relying solely on textbooks. While there are studies reporting that the distances of the infraorbital foramen to various anatomical points are higher on the right side, there are also studies measuring that they are higher on the left side<sup>24,25</sup>. In our study, morphometric measurements of the ZFF and IF were performed bilaterally, and most parameters showed no statistically significant differences between the right and left sides. This finding suggests that these structures generally exhibit

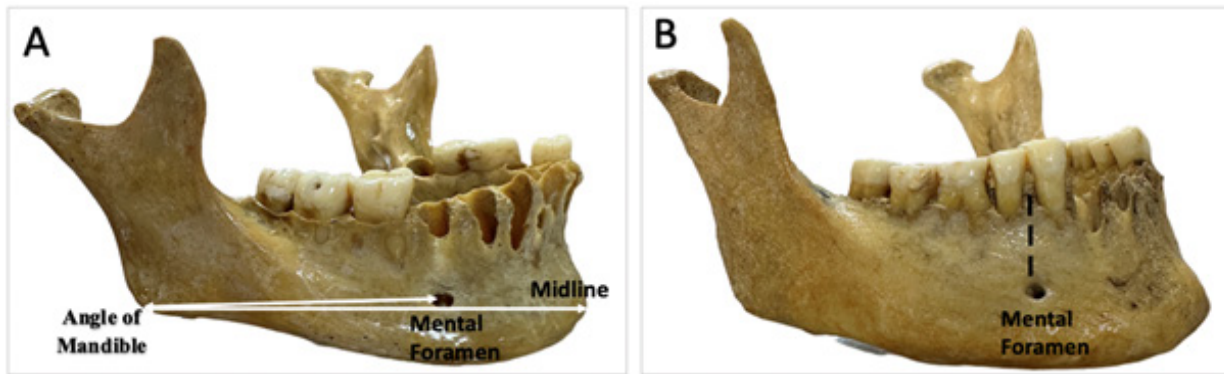


Figure 3: A: Schematic representation of the distances of the mental foramina to the specified points on the bone. B: Mental foramen located between the 1st and 2nd premolars

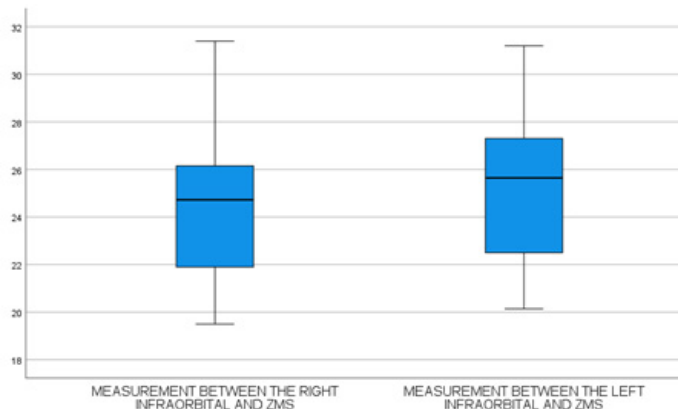


Figure 4: Boxplot graph of the left and right measurements of the infraorbital and ZMS (Zygomatico Maxillary Suture) diameter

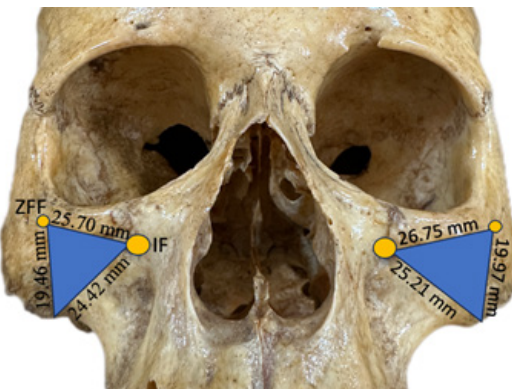

Figure 5: The schematic location of the foramen on the face, schematization of the area to be considered during injections in the blue area (Mean values were used in the schematization).

anatomical symmetry and supports the use of midline-based reference points during facial interventions. However, we found that the distance between IF and ZMS was significantly greater on the left side. This asymmetry may have clinical relevance in procedures involving infraorbital injections or zygomaticomaxillary approaches (such as infraorbital nerve blocks, periorbital surgeries, and aesthetic filler applications). Failure to account for such asymmetry may increase the risk of neurovascular injury or reduce the effectiveness of regional anesthesia.

Knowing the distance of the foramen to the orbital edge may be beneficial in preventing the injection of filler into the infraorbital artery, especially when applying filler under the eye. In the literature, it is recommended that filler injections be administered lateral to the infraorbital foramen. Therefore, accurate localization of the foramen is of critical importance<sup>26</sup>. According to our measurements, the intersection point of approximately 7.80 mm below the infraorbital edge and 24 mm medial to the outermost point

of the zygomatic arc can be used to locate the infraorbital foramen. In our study, we can identify areas (blue area) requiring attention, particularly in applications such as filler injections, based on the anatomical locations of the ZFF and IF (Figure 5). We recommend administering filler injections deeper into this area, as the vessels are likely to be more superficial.

We did not find any studies in the available literature that measured the distance between ZFF and ZTS. We performed our measurements based on the belief that this parameter could be used as a useful reference point in orbitozygomatic craniotomies, zygomatic implant placement, and subperiosteal midface lifts. Furthermore, in the context of aesthetic procedures such as filler injections into the malar and infraorbital regions, ZTS may help estimate the underlying course of the zygomaticofacial nerve.

In facial shaping surgeries, which are frequently preferred today, attention should be paid to the mental nerve for chin augmentation or chin reduction procedures. In the mandibular region, the distance from the mental foramen to the midline is important because midline approach is recommended for filler injection<sup>27</sup>. When we examined the distance of the mental foramen from the midline, we found values of 25.42 mm on the right and 25.46 mm on the left. These values are lower than the average (28.52 mm) found in the study by Apinhasmit et al<sup>28</sup>. Agarwall et al. found values similar to ours: 25.55 mm on the right and 25.05 mm on the left sides<sup>29</sup>. A study conducted in Britain reported that the location of the mental foramen was frequently between the first and second premolars<sup>30</sup>. Similar results were obtained in another study conducted in Africa<sup>31</sup>. However, there are racial differences in location. More than 50% of studies in the literature have found the mental foramen to be located at the level of the second premolar. In our study, we found it to be between the first and second premolars in 36% of cases on the right side and 33% on the left side. The second premolar location was the second most common location. Although the location of the mental foramen varies by race, it does not vary by gender<sup>32</sup>. From a clinical perspective, understanding the variability in mental foramen location is especially relevant in procedures such as: Mental nerve block, where misidentification of the foramen could result in anesthetic failure, mandibular osteotomies and implant surgeries, where foramen proximity may increase risk of nerve injury, and fracture fixation, where screw or plate placement must be adjusted to avoid impingement<sup>33</sup>. When we examined the morphometry of the mental foramen, we found it to be oval, similar to the literature. In our study, the accessory mental foramen was not present in any skull

bone. Unilateral and bilateral accessory mental foramina are commonly encountered in the literature. The presence of accessory foramina may indicate the presence of variational nerve bundles that may pass through here, which may cause failures in nerve blockade; therefore, these variations should be kept in mind<sup>32</sup>. According to our results; it is important that there is no significant difference between the distances of the foramina on the right and left to facilitate surgical and non-surgical interventions. These values can be used as anthropological markers. Moreover, awareness of asymmetries in the facial skeleton should guide clinicians to avoid assuming perfect symmetry during planning. This is particularly relevant in procedures performed bilaterally, where side to side discrepancies may otherwise be overlooked.

### Conflict of interest

The authors have no funding and conflicts of interest to disclose.

### Funding

The authors have no funding and conflicts of interest to disclose.

### Acknowledgements

None

### Ethical Approval

This study was conducted in accordance with the principles of the Declaration of Helsinki. Ethical approval was obtained from the Selcuk University Non-Interventional Research Ethics Committee (Approval Number:2024/295; Date:04.06.2024).

### Conclusion

In conclusion, the findings underscore the importance of precise morphometric mapping of facial foramina. While symmetry is generally preserved, certain parameters like the IF–ZMS distance exhibit clinically meaningful lateral variation. The lateral asymmetry in the IF–ZMS distance emphasizes the need for side specific anatomical assessment. These insights are especially valuable in guiding safe and effective facial interventions. In addition, this study confirms previous findings regarding bilateral symmetry of the mental foramen's dimensions and location. However, the substantial positional variability relative to premolars reinforces the need for individualized pre-surgical mapping of the foramen. Clinicians should be particularly cautious of posteriorly positioned foramina that may not align with expected landmarks.

### References

1. Aksu F, et al. Location and incidence of the zygomaticofacial foramen: an anatomic study. *Clin Anat.* 2009;22(5):559-562.
2. Gupta T. Localization of important facial foramina encountered in maxillo-facial surgery. *Clin Anat.* 2008;21(7):633-640.
3. Iwanaga J, Badaloni F, Watanabe K, et al. Anatomical study of the zygomaticofacial foramen and its related canal. *J Craniofac Surg.* 2018;29(5):1363-1365.
4. Ferro A, Basyuni S, Brassett C, Santhanam V. Study of anatomical variations of the zygomaticofacial foramen and calculation of reliable reference points for operation. *Br J Oral Maxillofac Surg.* 2017;55(10):1035-1041.
5. Deana NF, Alves N. Frequency and location of the zygomaticofacial foramen and its clinical importance in the placement of zygomatic implants. *Surg Radiol Anat.* 2020;42(7):823-830.

6. Khalid S, Iwanaga J, Loukas M, Tubbs RS. Bilateral absence of the zygomatic nerve and zygomaticofacial nerve and foramina. *Cureus.* 2017;9(7):e1505.
7. Song WC, Kim SH, Paik DJ, et al. Location of the infraorbital and mental foramen with reference to the soft-tissue landmarks. *Plast Reconstr Surg.* 2007;120(5):1343-1347.
8. Chrcanovic BR, Abreu MHNG, Custódio ALN. A morphometric analysis of supraorbital and infraorbital foramina relative to surgical landmarks. *Surg Radiol Anat.* 2011;33:329-335.
9. Haktanır A, Ilgaz K, Turhan-Haktanır N. Evaluation of mental foramina in adult living crania with MDCT. *Surg Radiol Anat.* 2010;32:351-356.
10. Ras F, Habets LLMH, Ginkel FC, Pahl-Andersen B. Three-dimensional evaluation of facial asymmetry in cleft lip and palate. *Cleft Palate Craniofac J.* 1994;31:116-121.
11. Rossi M, Ribeiro E, Smith R. Craniofacial asymmetry in development: an anatomical study. *Angle Orthod.* 2003;73(4):381-385.
12. Nikolova S, Toneva D. Bilateral asymmetry of Os Zygomaticum. *Acta Morphol Anthropol.* 2010;265.
13. Malevez C, Abarca M, Durdu F, Daelemans P. Clinical outcome of 103 consecutive zygomatic implants: a 6–48 months follow-up study. *Clin Oral Implants Res.* 2004;15:18-22.
14. Grant JR, LaFerriere KA. Periocular rejuvenation: lower eyelid blepharoplasty with fat repositioning and the suborbicularis oculi fat. *Facial Plast Surg Clin North Am.* 2010;18(3):399-409.
15. Kim HS, et al. Three-dimensional courses of zygomaticofacial and zygomaticotemporal canals using micro-computed tomography in Korean. *J Craniofac Surg.* 2013;24(5):1565-1568.
16. Fibiger G, Majka K, Obrzut J, et al. Zygomaticofacial foramen and its surgical anatomy in plastic and maxillofacial surgery—a systematic review with a meta-analysis. *Folia Morphol.* 2025; 84(4):858-870.
17. Ongeti K, Hassanali J, Ogeng'o J, Saidi H. Biometric features of facial foramina in adult Kenyan skulls. *Eur J Anat.* 2008;12(2):89-95.
18. Kazkayasi M, Ergin A, Ersoy M, et al. Certain anatomical relations and the precise morphometry of the infraorbital foramen–canal and groove: an anatomical and cephalometric study. *Laryngoscope.* 2001;111:609-614.
19. Cutright B, Quillopa N, Schubert W. An anthropometric analysis of the key foramina for maxillofacial surgery. *J Oral Maxillofac Surg.* 2003;61:354-357.
20. Aziz S, Marchena J, Puran A. Anatomic characteristics of the infraorbital foramen: a cadaver study. *J Oral Maxillofac Surg.* 2000;58:992-996.
21. Rahman M, Richter EO, Osawa S, Rhoton AL. Anatomic study of the infraorbital foramen for radiofrequency neurotomy of the infraorbital nerve. *Neurosurgery.* 2009;64:423-428.
22. Aggarwal A, Kaur H, Gupta T, et al. Anatomical study of the infraorbital foramen: a basis for successful infraorbital nerve block. *Clin Anat.* 2015;28(6):753-760.
23. Saheb SH, Shruthi BN, Havaladar PP. A study on position of infraorbital foramen. *Int J Anat Res.* 2017;5(3.2):4257-4260.
24. Gnanagurudasan E, Ahamed SR, Deepalaxmi S, Gnanadesigan E. A genderwise study on the morphometry of infraorbital foramen and its laterality in dry adult skulls of south Indian population. *Int J Med Sci Public Health.* 2014;3(5): 546-548. doi:10.5455/ijmsph.2014.210220141
25. Martins-Júnior PA, Rodrigues CP, De Maria ML, et al. Analysis of anatomical characteristics and morphometric aspects of infraorbital and accessory infraorbital foramina. *J Craniofac Surg.* 2017;28(2):528-533.
26. Clark NW, Pan DR, Barrett DM. Facial fillers: relevant anatomy, injection techniques, and complications. *World J Otorhinolaryngol*  
<https://dx.doi.org/10.4314/mmj.v38i2.10>

Head Neck Surg. 2023;9(3):227-235.

27.Wollina U, Goldman A. Facial vascular danger zones for filler injections. *Dermatol Ther.* 2020;33(6):e14285.

28.Apinhasmit W, et al. Supraorbital notch/foramen, infraorbital foramen and mental foramen in Thais: anthropometric measurements and surgical relevance. *J Med Assoc Thai.* 2006;89(5):675-682.

29.Agarwal DR, Gupta SB. Morphometric analysis of mental foramen in human mandibles of South Gujarat. *People's J Sci Res.* 2011;4(1):15-18.

30.Santini A, Land M. A comparison of the position of the mental foramen in Chinese and British mandibles. *Acta Anat (Basel).* 1990;137:208-212.

31.Mwaniki DL, Hassanali J. The position of mandibular and mental foramina in Kenyan African mandibles. *East Afr Med J.* 1992;69:210-213.

32.Moodley S, Ishwarkumar S, Pillay P. Localisation of the supraorbital, infraorbital and mental foramina: a review. *Transl Res Anat.* 2023;32:100257.

33.Apinhasmit W, Methathrathip D, Chompoopong S, Sangvichien S. Mental foramen in Thais: an anatomical variation related to gender and side. *Surg Radiol Anat.* 2006;28(5):529-533.